

## ROOT CANAL MORPHOLOGY OF MANDIBULAR PREMOLARS IN NORTH INDIAN POPULATION USING TOOTH CLEARING TECHNIQUE – AN IN VITRO STUDY

Gurkirat Singh Grewal<sup>1</sup>, Ajay Chhabra<sup>2</sup>, Varun Jindal<sup>3</sup>, Simran Pal Singh Bindra<sup>4</sup>, Vandana Chhabra<sup>5</sup>, Damanpreet<sup>6</sup>

<sup>1</sup>Senior Lecturer, Department of Conservative Dentistry & Endodontics, Bhojia Dental College & Hospital, Himachal Pradesh, India

<sup>2</sup>Professor & Head, Department of Conservative Dentistry & Endodontics, Bhojia Dental College & Hospital, Himachal Pradesh, India

<sup>3</sup>Reader, Department of Conservative Dentistry & Endodontics, Bhojia Dental College & Hospital, Himachal Pradesh, India

<sup>4</sup>P.G. Student, Department of Conservative Dentistry & Endodontics, Bhojia Dental College & Hospital, Himachal Pradesh, India

<sup>5</sup>Reader, Department of Oral and Maxillofacial Surgery, SKSS Dental College, Punjab, India

<sup>6</sup>Reader, Department of Conservative Dentistry & Endodontics, Bhojia Dental College & Hospital, Himachal Pradesh, India

### ABSTRACT

**Aim:** The aim of this study was to investigate the root canal morphology of mandibular premolars in Northern region of India using a decalcification and clearing technique. **Method:** Three hundred extracted human mandibular premolars, collected from dental clinics within North India were selected for this study. Following pulp tissue removal, India ink was injected into the root canals and the teeth were decalcified with 5% nitric acid, dehydrated with ascending concentrations of alcohol and rendered clear by immersion in methyl salicylate. Cleared teeth were examined under 5X magnification and the following features were evaluated: (i) number and type of root canals; (ii) presence and location of lateral canals and; (iii) location of apical foramina. **Results:** 84.2% of the specimens exhibited Type I canal pattern. Type VIII was not observed in any of the specimens. The lateral canals were in the apical third in 78.7% of the specimens followed by middle third in 16.5% and the cervical third in 4.7%. 82.7% of the specimens showed lateral position of the apical foramen. **Conclusion:** Mandibular premolar teeth present a wide variety of radicular features, with one root and one canal being found in majority of the cases. An accurate knowledge of the morphology of the root canal is essential for proper diagnosis and successful treatment of endodontic cases.

**Keywords:** Mandibular Premolars, Root Canal, Morphology, Vertucci's Classification, Tooth Clearing

### INTRODUCTION

In the study of human anatomy, root canal morphology of teeth is most captivating as well as the most difficult to classify.<sup>1</sup> The relative simplicity and uniformity of the external surfaces of roots often masks their internal complexity. Studies on the internal and external anatomy of teeth have shown that anatomic variations can occur in all groups of teeth and can be extremely complex.<sup>2, 3</sup> Numerous factors contribute to the variations found in the root canal studies including ethnicity,<sup>1</sup> age,<sup>4</sup> gender<sup>5</sup> and study design<sup>6</sup> (in vitro versus in vivo).

The wide range of studies conducted on root canal anatomy, from the early work of Hess & Zurcher 1925 to

the most recent,<sup>1,5</sup> demonstrating anatomic complexities of the root canal system, have all emphasized on the fact that a root with a graceful, tapering canal and a single apical foramen is an exception rather than the rule.<sup>7</sup> Allen et al<sup>8</sup> stated that even though the complex webs, fins and communications do not contribute significantly to outcome, it is clear that many factors including knowledge of canal numbers and divisions may contribute to the predictability of overall endodontic treatment.

Brescia 1961 reported that the mandibular first premolar teeth had the most variable canal pattern.<sup>9</sup> A study at the University of Washington 1955 assessed the failure rate of non surgical root canal treatment in all teeth. The mandibular first

Corresponding Author:  
Gurkirat Singh Grewal  
E-mail:

gurkirat.grewal@gmail.com

Received: 10<sup>th</sup> August 2015

Accepted: 3<sup>rd</sup> November 2015

Online: 11<sup>th</sup> January 2016

premolar had the highest failure rate in the study at 11.45%. Possible reasons for this conclusion are the numerous variations in root canal morphology and difficult access to additional canal systems when present.<sup>10</sup> Slowey has suggested that mandibular first premolars, often called as “Endodontic enigma,” may present the greatest difficulty of all teeth to perform successful endodontic treatment.<sup>11</sup>

The studies on root canal morphology of mandibular premolars were mainly performed in United States of America,<sup>3,12,13,14</sup> China,<sup>15,16,17,18</sup> Sweden,<sup>19</sup> Turkey,<sup>5,20,21</sup> United Kingdom,<sup>22,23</sup> Austria,<sup>24</sup> New Zealand,<sup>25</sup> Poland<sup>26</sup> and Iran.<sup>27</sup>

Asian populations present one of the widest variations in coronal shape, external root form and internal canal space morphology.<sup>28</sup> It is therefore considered important to be familiar with variations in tooth/canal anatomy and characteristic features in various racial groups.<sup>29</sup> Such knowledge can aid location and negotiation of canals as well as their subsequent management. Studies on the root canal morphology amongst the Indian population are rare.<sup>30</sup>

A variety of techniques has been used to study the anatomy of the root canal system. These techniques have included decalcification and clearing,<sup>1,3,7</sup> direct observation with microscope,<sup>31</sup> radiography,<sup>32</sup> sectioning and macroscopic observation,<sup>15,33</sup> 3D reconstruction,<sup>34</sup> contrast medium-enhanced radiography<sup>35,36</sup> and more recently computed tomographic techniques.<sup>17,24,29,36-38</sup> The other techniques that had also been used are grinding out of teeth, metal filling of pulp cavities and corrosion, iontophoresis, injections and plastic embeddings.<sup>39</sup>

The present study was conducted using the decalcification and tooth clearing technique because it is considered as the gold standard<sup>38</sup> for analyzing the root canal anatomy. Vertucci<sup>40</sup> has also reported that the most detailed information can be obtained *ex vivo* by demineralization and staining. Unlike radiographic images, the clearing technique provides a three-dimensional view of the pulp cavity in relation to the exterior of the teeth and allows a comprehensive examination of the pulp chamber and root canal system.<sup>41</sup>

A few studies on mandibular premolars have been carried out in India like Gujarat<sup>28</sup> and Chennai.<sup>9,42-43</sup> Sikri et al<sup>44</sup> evaluated the root canal morphology of mandibular premolars in Amritsar (Punjab). No other data is available on root canal morphology of mandibular premolars in northern region of India.

Therefore, the following study was conducted to investigate, in detail, the root canal morphology of mandibular premolars in Northern region of India using a decalcification and clearing technique.

## MATERIALS AND METHODS

A total of 300 extracted mandibular premolars were randomly collected from general dental clinics within North India. The gender and age of patients was unknown, and no attempt was made to differentiate between first and second mandibular premolars. Hard and soft deposits were removed using hand-scaling instruments scrubbed under tap water. Teeth with root fractures (n=3), immature apices (n=10), root caries (n=5) and resorption (n=2) were excluded. The samples were stored in 5.25% sodium hypochlorite (Dentpro, Amrit chemicals Ltd, Mohali, Punjab, India) for 30 minutes for the removal of organic debris and then in 10% formaldehyde until further steps.

The pulp chambers were assessed using round bur (Mani) and Endo Z bur (Dentsply International) in a high speed handpiece (NSK, Japan) and the pulp tissue was removed from the canal orifices with the No. 10 K file (Mani). India ink (Himedia Laboratories Pvt. Ltd., Mumbai, India) was injected into the root canals using syringes with a 27 gauge needle (Sterican, Braun Medical India Pvt. Ltd., Mumbai, India) under negative pressure at the apical end.

Samples were then kept in 5% nitric acid solution (Aries Laboratories, Ahmedabad, India) for 5 days. The solution was changed daily while agitating it three times a day. Demineralisation was assessed with the help of Radiovisiography. The teeth were then rinsed under running water for 4 hours and dehydrated in solutions of 70%, 80% and 95% ethyl alcohol successively for 24 hours. At the end of this period, no radiopacity was observed.

Samples were then placed in methyl salicylate (Vikas Pharma, Mumbai, India) to enhance the translucency. At the end of the third day, complete transparency was achieved.

Teeth in which dye did not penetrate till the apical end were excluded (n=5).

The samples were then examined under Stereomicroscope (5X) (Olympus, Tokyo, Japan), and the following observations were made:

- (i) Type of root canals
- (ii) Presence and location of lateral canals
- (iii) Location of apical foramina

Canals were categorised according to Vertucci's<sup>40</sup> classification (Figure 1) as follows:

The samples that were not included in Vertucci's<sup>40</sup> Classification 1984 were categorised according to Gulabivala's<sup>1</sup> Classification 2001 (n=2; Figure 2) and Sert & Bayirli's<sup>5</sup> classification 2004 (n=1; Figure 3).

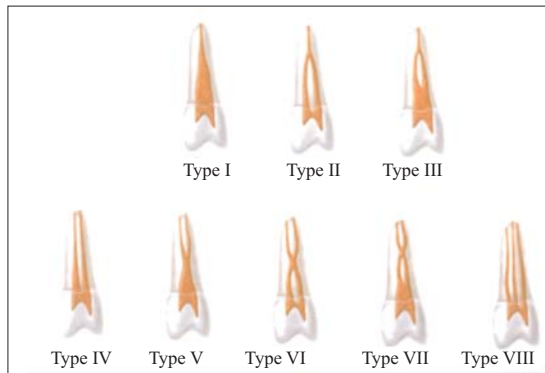


Figure 1: Vertucci's Classification

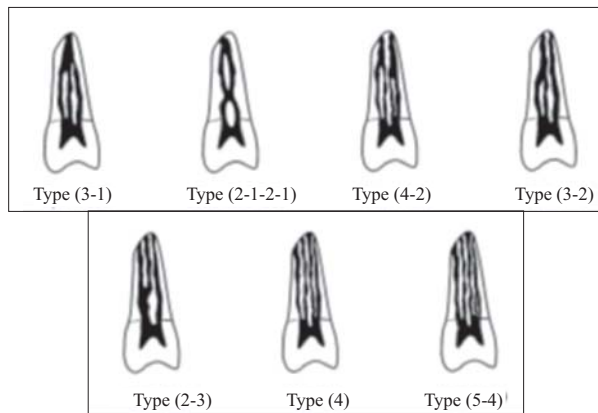


Figure 2: Gulabivala's Classification

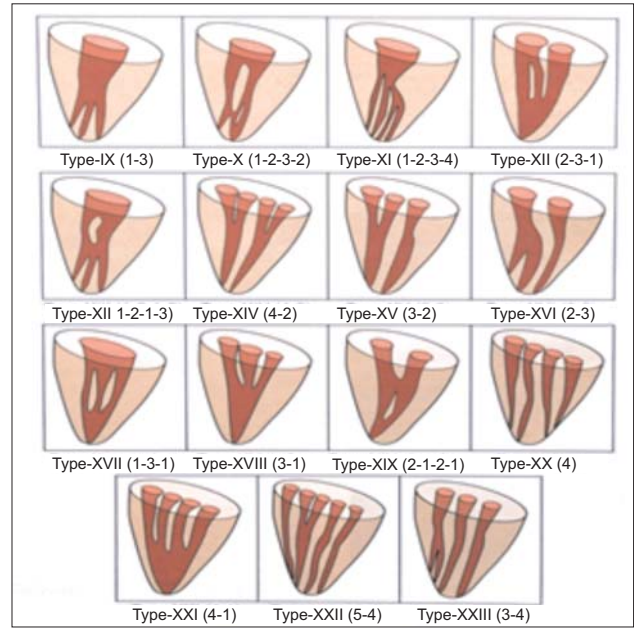


Figure 3: Sert and Bayirli's additional canal types

## RESULTS

84.2% of the specimens exhibited Type I canal pattern. Type V was the second most common canal pattern as observed in 10.3 % of the specimens. Type II, Type III, Type IV canal patterns were evident in 1.5%, 1.8%, 1.1% of the specimens. 0.7%, 0.4% of the samples stained Type VI, Type VII canal pattern. Type VIII was not observed in any of the specimens (Table 1; Figure 4).

Table 1: Type & Number of Root Canals

Type	Number of teeth	Percentage
Type I	229	84.2
Type II	4	1.5
Type III	5	1.8
Type IV	3	1.1
Type V	28	10.3
Type VI	2	0.7
Type VII	1	0.4
Type VIII	Zero	Zero

Of 272 samples in the study, lateral canals were observed in 127 teeth (46.7%). The lateral canals were found most often in the apical third (78.7%) followed by middle third (16.5%) and the cervical third (4.7%) (Table 2).

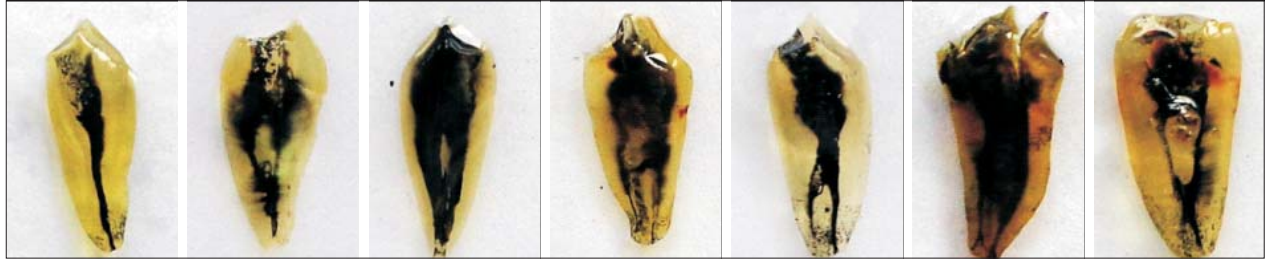

Figure 4: Types of Root Canal's According to Vertucci

Table 2: Presence and location of lateral canals

Position of lateral canals	No. of teeth	Percentage
Cervical	6	4.7
Middle	21	16.5
Apical	100	78.7

The apical foramen was found to coincide with the apical root tip only in 17.3% of the cases. Majority of the specimens (82.7%) show lateral position of the apical foramen (Table 3).

Table 3: Location of apical foramen

Position	No. of teeth	Percentage
Central	47	17.3
Lateral	225	82.7

## DISCUSSION

The study of root and canal anatomy has endodontic and anthropological significance.<sup>22,29</sup> It is important to be familiar with the variations in the root canal anatomy. Slight deviations from the original root path can cause procedural accidents (ledging, perforation or root fracture) during endodontic treatment, post space preparation, and post insertion.<sup>32</sup>

The complexity of the root and root canal morphology of the mandibular first premolar may have been underestimated in the past. A thorough review of the literature reveals both complex root morphology as well as complex internal canal morphology.<sup>45</sup> The studies by Serman and Hasselgren<sup>46</sup> as well as the study by Trope et al<sup>13</sup> reported higher incidences of multiple root canal in their studies (7% and 3.1%, respectively) compared with the averages reported in the anatomic studies (0.4%). ElDeeb<sup>47</sup> (1982), Shapira & Delivanis<sup>48</sup> (1982) and Rodig & Hulsmann<sup>49</sup> (2003) reported a mandibular second premolar with three canals, whereas Bram & Fleisher<sup>50</sup> (1991), Wong<sup>51</sup> (1991), Holtzman<sup>52</sup>

(1998), Rhodes<sup>53</sup> (2001), Macri & Zmener<sup>54</sup> (2000) and Sachdeva GS et al<sup>55</sup> (2008) reported cases of mandibular second premolars with four canals, some with serious clinical outcomes.

In the present study, root canal system of mandibular premolars with Type I canal pattern was found to be predominantly 84.2%. The results are in concurrence with a study reported by Vertucci,<sup>40</sup> and Sandhya, Velmurugan & Kandaswami<sup>43</sup> who reported an incidence of 80% in mandibular first premolars.

The present study showed Type II canal pattern in 1.5% of the teeth which is similar to the findings by Iyer VH et al<sup>56</sup> (1% in case of mandibular premolars). Rahimi et al<sup>57</sup> reported the incidence of Type II canal pattern in 1.9% of the mandibular first premolars, but the observations were different regarding mandibular second premolars (7.9%).

Type III canal system was found in 1.8% of the teeth which is similar to the findings of Awawdeh & Qudah,<sup>7</sup> who reported Type III canal pattern in 1.4% of the mandibular first premolars and 1% in mandibular second premolars. The findings by Vertucci<sup>40</sup> were 4% in mandibular first premolars.

Type IV canal system was found in 1.1% mandibular premolars which is in accordance with Vertucci,<sup>40</sup> Sandhya, Velmurugan & Kandaswami<sup>43</sup> and Jain & Bahuguna<sup>28</sup> who reported this system in 1.5%, 2% and 2.89% of mandibular first premolar teeth. Iyer VH et al<sup>56</sup> reported Type IV canal pattern in 20.8% of the mandibular premolars.

Type V canal pattern was the second most common canal pattern as observed in 10.3 % of the specimens which is similar to study by Velumurgan & Sandhya<sup>9</sup> who reported an incidence of 8% in



mandibular first premolars. Yang H et al<sup>58</sup> and Caliskan MK et al<sup>20</sup> reported Type V canal pattern in 9.32 and 9.43% of mandibular first premolars. Sert, Aslanap & Tanalp<sup>21</sup> reported Type V canal pattern in 7% of the mandibular second premolars.

0.7% of the samples stained Type VI canal pattern which is in concurrence with the findings by Jain & Bahuguna<sup>28</sup> and Awawdeh & Qudah<sup>7</sup> who reported incidence of 0.72% and 0.8% in case of mandibular first premolars. Vertucci<sup>40</sup> did not report Type VI canal pattern in mandibular premolar teeth.

Type VII canal pattern was found in 0.4% of the teeth. The results are similar to the studies by Rahimi et al<sup>57</sup> who reported Type VII canal pattern in 0.6% of the mandibular first premolars and none in mandibular second premolars. Vertucci<sup>40</sup> and Caliskan MK et al<sup>20</sup> reported 0% incidence of Type VII canal pattern in mandibular first and second premolars.

Type VIII canal pattern was not observed in any of the specimens. Rahimi et al<sup>57</sup> also did not observe Type VIII canal pattern in mandibular premolars. Sandhya, Velmurugan & Kandaswami<sup>43</sup> and Jain & Bahuguna<sup>28</sup> failed to observe Type VIII canal pattern in mandibular first premolars. Vertucci<sup>40</sup> reported Type VIII canal pattern in 0.5% of the mandibular first premolars and none in mandibular second premolars.

The two samples that fell into Gulabivala's classification consisted of Type (3-1) and Type (2-1-2-1) canal pattern (Figure 5). The remaining one specimen consisted of Sert & Bayirli's Type IX canal pattern (Figure 6).

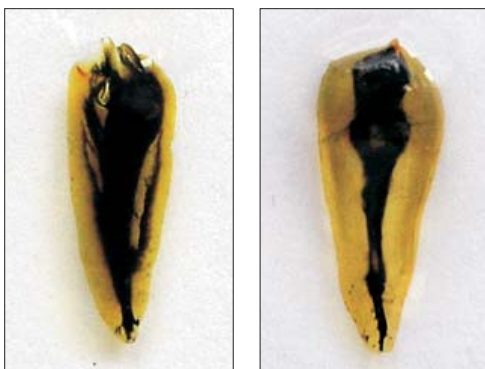

Figure 5: Gulabivala's Type (3-1) & (2-1-2-1) canal pattern

Lateral canals were observed in 46.7% of the teeth in the present study. The lateral canals were found predominantly in the apical third (78.7%; Figure 7) followed by middle third (16.5%; Figure 8) and the cervical third (4.7%; Figure 9). The findings of the study are in concurrence with a study reported by Vertucci<sup>40</sup> who reported the presence of lateral canals in 44.3% of mandibular first premolars and 48.3% in mandibular second premolars.

The present study showed the apical foramen to coincide with the apical root tip only in 17.3% of the cases (Figure 10) while 82.7% of the specimens showed lateral position of the apical foramen (Figure 11). The findings are similar to the study by Vertucci<sup>40</sup> which reported location of the apical foramen on the lateral side in 85% of the mandibular first premolars and 83.9% in mandibular second premolars. Apex was

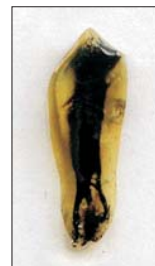

Figure 6: Sert & Bayirli's Type IX canal pattern

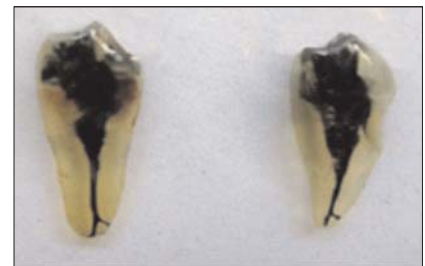

Figure 7: Lateral canals at the apical third

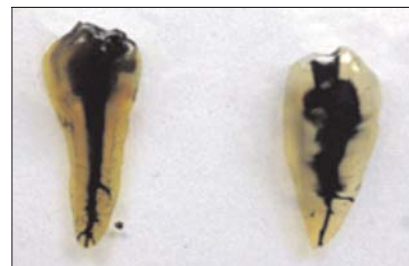

Figure 8: Lateral canals at the middle third



Figure 9: Lateral canals at the coronal & middle third

located at the centre in 15% of the mandibular first premolars and 16.1% of the mandibular second premolars.

The difference in the incidence of the root canal system, presence and position of lateral canals

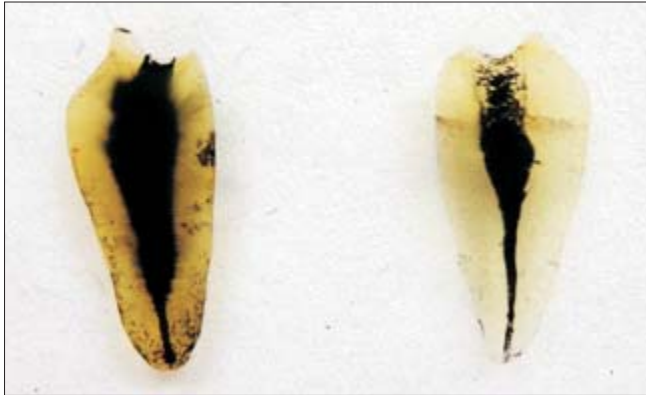

Figure 10: Apical foramen located at the centre



Figure 11: Lateral exit of the apical foramen

and apical foramen in the present study and those compared with could be attributed to racial difference. Different studies have looked at the root canal morphology of mandibular premolars over the years and pointed out that the root canal types may vary according to race<sup>5, 13, 59, 60</sup>

The most detailed three dimensional evaluation can be obtained by demineralization and staining.<sup>4, 40, 61</sup> The technique is simple to perform, rapid and gives good results in few days. The complete penetration of dye was achieved using negative pressure of 60 Torr at the apical end as suggested by Antonopoulos, Attin and Hellwig.<sup>62</sup> Incomplete or uneven decalcification was avoided in the present study by agitation of acid three times a day, having sufficient volume of acid, daily changes of acid solution, and not stacking teeth during demineralization as demineralization occurs more rapidly at the top of the container than at the bottom. Methyl salicylate tolerates

more water and is less noxious than other clearing agents such as xylene.<sup>63</sup>

## CONCLUSION

An accurate knowledge of the morphology of the pulp cavity is essential before an endodontic procedure can be approached rationally. The dentist also should be aware of the possible existence of bifurcated and double canals if root canal therapy unexpectedly fails. A thorough knowledge of these variations will assist the dentist in reaching conclusions when diagnosing and treating endodontic cases.

## REFERENCES

1. Gulabivala K, Anug TH, Alavi A, Ng Y-L. Root and canal morphology of Burmese mandibular molars. *Int Endod J* 2001;34:359-370
2. Cohen S, Burns RC. *Pathways of the Pulp*. 5th ed. St. Louis: Mosby; 2002. p. 173-228
3. Vertucci FJ. Root canal morphology and its relationship to endodontic procedures. *Endodontic Topics* 2005;10:3-29
4. Neaverth EJ, Kotler LM, Kaltenbach RF. Clinical investigation (in vivo) of endodontically treated maxillary first molars. *J Endod* 1987;13(10):506-512
5. Sert S, Bayirli GS. Evaluation of the root canal configurations of the mandibular and maxillary permanent teeth by gender in the Turkish population. *J Endod* 2004;30(6):391-398
6. Awawdeh L, Abdullah H, Al-Qudah A. Root form and canal morphology of Jordanian maxillary first premolars. *J Endod* 2008;34(8):956-961
7. Awawdeh LA, Al-Qudah AA. Root form and canal morphology of mandibular premolars in a Jordanian population. *Int Endod J* 2008;41:240-248
8. Allen RK, Newton CW, Brown CE. A statistical analysis of surgical and non-surgical endodontic retreatment cases. *J Endod* 1989;15(6):261-266
9. Velmurugan N, Sandhya R. Root canal morphology of mandibular first premolars in an Indian population: a laboratory study. *Int Endod J* 2009;42:54-58
10. Ingle J, Bakland L. *Endodontics*, 5th ed. Hamilton: BC Decker, 2002
11. Kararia N, Chaudhary A, Kararia V. Mandibular left first premolar with two roots: A morphological oddity. *Contemp Clin Dent* 2012;3(2):234-236
12. Barrett MT. The internal anatomy of the teeth with special reference to the pulp with its branches. *Dent Cosmos* 1925;67(6):581-592

13. Trope M, Elfenbein L, Tronstad L. Mandibular premolars with more than one root canal in different race groups. *J Endod* 1986;12(8):343-345
14. Gullickson DC, Montgomery S. The study of root canal morphology using a digital image processing technique. *J Endod* 1987;13(4):158-163
15. Lu TY, Yang SF, Pai SF. Complicated root canal morphology of mandibular first premolar in a Chinese population using the cross section method. *J Endod* 2006;32(10):932-936
16. Walker RT. Root canal anatomy of mandibular first premolars in a southern Chinese population. *Endod Dent Traumatol* 1988;4:226-228
17. Fan B, Yang J, Gutmann JL, Fan M. Root canal systems in mandibular first premolars with C-shaped root configurations. Part I: Microcomputed tomography mapping of the radicular groove and associated root canal cross-sections. *J Endod* 2008;34(11):1337-1341
18. Fan B, Ye W, Xie E, Wu H, Gutmann JL. Three-dimensional morphological analysis of C-shaped canals in mandibular first premolars in a Chinese population. *Int Endod J* 2012;45:1035-1041
19. Kerkes K, Tronstad L. Morphometric observations on root canals of human premolars. *J Endod* 1977;3(2):74-79
20. Caliskan MK, Pehlivan Y, Sepetcioglu F, Turkun M, Tuncer SS. Root canal morphology of human permanent teeth in a Turkish population. *J Endod* 1995;21(8):200-204
21. Sert S, Aslanalp V, Tanalp J. Investigation of the root canal configurations of mandibular permanent teeth in the Turkish population. *Int Endod J* 2004;37:494-499
22. Bedford JM, Martin DM, Youngson CC. Assessment of a contrast medium as an adjunct to endodontic radiography. *Int Endod J* 2004;37:806-813
23. Nattress BR, Martin DM. Predictability of radiographic diagnosis of variations in root canal anatomy in mandibular incisor and premolar teeth. *Int Endod J* 1991;24:58-62
24. Robinson S, Czerny C, Gahleitner A, Bernhart T, Kainberger FM. Dental CT evaluation of mandibular first premolar root configurations and canal variations. *Oral Surg Oral Med Oral Pathol Oral Radiol Endod* 2002;93:328-332
25. Kelsen AE, Love RM, Kieser JA, Herbison P. Root canal anatomy of anterior and premolar teeth in Down's syndrome. *Int Endod J* 1999;32:211-216
26. Kusiak A, Sadlak-Nowicka J, Limon J, Kochanska B. Root morphology of mandibular premolars in 40 patients with Turner syndrome. *Int Endod J* 2005;38:822-826
27. Khedmat S, Assadian H and Saravani AA. Root canal morphology of the mandibular first premolars in an Iranian population using cross-sections and radiography. *J Endod* 2010;36(2):214-217
28. Jain A, Bahuguna R. Root canal morphology of mandibular first premolar in a Gujarati population-an in vitro study. *Dent Res J* 2011;8(3):118-122
29. Walker RT. Root form and canal anatomy of mandibular first molars in a Southern Chinese population. *Endod Dent Traumatol* 1988;4:19-22
30. Reuben J, Velmurugan N, Kandaswamy D. The evaluation of root canal morphology of the mandibular first molar in an Indian population using spiral computed tomography scan: An in vitro study. *J Endod* 2008;34(2):212-215
31. Sempire HN, Hartwell GR. Frequency of second mesiobuccal canals in maxillary molars as determined by use of an operating microscope: A clinical study. *J Endod* 2000;26(11):673-674
32. Willershausen B, Tekyatan H, Kasaj A, Marroquin BB. Roentgenographic in vitro investigation of frequency and location of curvatures in human maxillary premolars. *J Endod* 2006;32(4):307-311
33. Baisden MK, Kulild JC, Weller RN. Root canal configuration of the mandibular first premolar. *J Endod* 1992;18(10):505-508
34. Mikrogeorgis G, Lyroudia KL, Nikopoulos N, Pitas I, Molyvdas I, Lambrianidis TH. 3D computer-aided reconstruction of six teeth with morphological abnormalities. *Int Endod J* 1999;32:88-93
35. Fan B, Gao Y, Fan W, Gutmann JL. Identification of a C-shaped canal system in mandibular second molars-part II: The effect of bone image superimposition and intraradicular contrast medium on radiograph interpretation. *J Endod* 2008;34(2):160-165
36. Neelakantan P, Subbarao C, Subbarao CV. Comparative evaluation of modified canal staining and clearing technique, cone beam computed tomography, peripheral quantitative computed tomography, spiral computed tomography, and plain and contrast medium-enhanced digital radiography in studying root canal morphology. *J Endod* 2010;36(9):1547-1551
37. Sberna MT, Rizzo G, Zacchi E, Cappare P, Rubinacci A. A preliminary study of the use of peripheral quantitative computed tomography for investigating root canal anatomy. *Int Endod J* 2009;42:66-75
38. Kim Y, Lee S-J, Woo J. Morphology of maxillary first and second molars analyzed by cone-beam computed tomography

- in a Korean population: Variations in the number of roots and canals and the incidence of fusion. *J Endod* 2012;38(8):1063-1068
39. Deus QDD, Horizonte B. Frequency, location and direction of the lateral, secondary and accessory canals. *J Endod* 1975;1(11):361-366
  40. Vertucci FJ. Root canal anatomy of human permanent teeth. *Oral Surg* 1984;58:589-599
  41. Vertucci FJ. Root canal morphology of mandibular premolars. *JADA* 1978;97(1):47-50
  42. Raj UJ, Sumitha M. Root canal morphology of maxillary second premolars in an Indian population. *J Conserv Dent* 2010;13(3):148-151
  43. Sandhya R, Velmurugan N, Kandaswamy D. Assessment of root canal morphology of mandibular first premolars in the Indian population using spiral computed tomography: An *in vitro* study. *Indian J Dent Res* 2010;21(2):169-173
  44. Sikri VK, Sikri P. Mandibular premolars: Aberrations in pulp space morphology. *Ind J Dent Res* 1994;5:9-14
  45. Cleghorn BM, Christie WH, Dong CCS. The root and root canal morphology of the human mandibular first premolar: A literature review. *J Endod* 2007;33(5):509-516
  46. Serman NJ, Hasselgren G. The radiographic incidence of multiple roots and canals in human mandibular premolars. *Int Endod J* 1992;25:234-237
  47. Eldeeb ME. Three root canals in mandibular premolars: literature review and a case report. *J Endod* 1982;8(8):376-377
  48. Shapira Y, Delivanis. Multiple-rooted mandibular second premolars. *J Endod* 1982;8(5):231-232
  49. Rodig T, Hulsmann M. Diagnosis and root canal treatment of a mandibular second premolar with three root canals. *Int Endod J* 2003;36:912-919
  50. Bram SM, Fleisher R. Endodontic therapy in a mandibular second bicuspid with four canals. *J Endod* 1991;17(10):513-515
  51. Wong M. Four root canals in a mandibular second premolar. *J Endod* 1991;17(3):125-126
  52. Holtzman L. Root canal treatment of mandibular second premolar with four root canals: A case report. *Int Endod J* 1998;31:364-366
  53. Rhodes JS. A case of an unusual anatomy of a mandibular second premolar with four canals. *Int Endod J* 200;34:645-648
  54. Macri E, Zmener O. Five canals in a mandibular second premolar. *J Endod* 2000;26(5):304-305
  55. Sachdeva GS, Ballal S, Gopikrishna V, Kandaswamy D. Endodontic management of a mandibular second premolar with four roots and four root canals with the aid of spiral computed tomography: A case report. *J Endod* 2008;34(1):104-107
  56. Iyer VH, Indira R, Ramachandran S, Srinivasan MR. Anatomical variations of mandibular premolars in Chennai population. *Ind J Dent Res* 2006;17(1):7-10
  57. Saeed Rahimi, Shahriar Shahi, Hamid Reza Yavari, Hakimeh Manafi, Nemat Eskandarzadeh. Root Canal Configuration of mandibular first and second premolars in an Iranian population. *J Dent Res Dent Clin Dent Prospects* 2007;1(2):59-64
  58. Yang H, Tian C, Li G, Yang L, Han X, Wang Y. A cone-beam computed tomography study of the root canal morphology of mandibular first premolars and the location of root canal orifices and apical foramina in a Chinese population. *J Endod* 2013;39(4):435-438
  59. Kim E, Fallahrestegar A, Hur Y-Y, Jung I-Y, Kim S, Lee S-J. Difference in root canal length between Asians and Caucasians. *Int Endod J* 2005;38:149-151
  60. Lu TY, Yang SF, Pai SF. Complicated root canal morphology of mandibular first premolar in a Chinese population using the cross section method. *J Endod* 2006;32(10):932-936
  61. Sieraski SM, Taylor GN, Kohn RA. Identification and endodontic management of three-canal maxillary premolars. *J Endod* 1989;15(1):29-32
  62. Antonopoulos KG, Attin T, Hellwig E. Evaluation of the apical seal of root canal fillings with different methods. *J Endod* 1998;24(10):655-658
  63. Robertson D, Leeb J, McKee M, Brewer E. A clearing technique for the study of root canal systems. *J Endod* 1980;6(1):421-424

**Source of Support: Nil, Conflict of Interest: None Declared**