

“VERTICAL ROOT FRACTURE”- A DILEMMA REVISITED

Navneet Kukreja¹, Disha Agarwal², Abhishek Bansal³, Devendra Chaudhary⁴, Urvashi Kukreja⁵, Sangam Mittal⁶

¹Professor, Department of Conservative Dentistry & Endodontics, MM College of Dental Sciences & Research, Haryana, India

²PG Student, Department of Conservative Dentistry and Endodontics, MM College of Dental Sciences & Research, Haryana, India

³Reader, Department of Conservative Dentistry & Endodontics, MM College of Dental Sciences & Research, Haryana, India

⁴Professor & Head, Department of Conservative Dentistry & Endodontics, Maharaja Ganga Singh Dental College, Rajasthan, India

⁵Reader, Department of Prosthodontics, MM College of Dental Sciences & Research, Haryana, India

⁶PG Student, Department of Conservative Dentistry and Endodontics, MM College of Dental Sciences & Research, Haryana, India

ABSTRACT

Diagnosis of vertical root fracture in an endodontically treated tooth presents with various difficulties. The diagnosis of such a fracture is a challenge to the clinician since it is based on subjective parameters. There are, however, many specific clinical and radiographical signs which, when present, can alert clinicians to the existence of such a fracture. Various methods to clinically diagnose vertical root fracture include conventional methods such as illumination, periodontal probing, staining, direct visual examination and newer techniques such as cone beam computed tomography, optical coherence tomography. The management of a vertical root fracture has always been considered a difficult task for the endodontist. This article provides an insight into the various methods of diagnosis and treatment strategies for the vertical root fracture.

Keyword: Diagnosis, Etiology, Vertical Root Fracture.

INTRODUCTION

Gibbs¹ was one of the first to describe the problem of pain during mastication that was unrelated to caries or infected teeth. "A vertical root fracture is a longitudinally oriented fracture of the root that originates from the apex and propagates to the coronal part" as defined by American Association of Endodontists (AAE).² From a horizontal aspect, the fracture initiates in the root canal wall and extends to the root surface, involving either one side (incomplete) or both sides (complete fracture).³

Vertical root fractures belongs to one of the five categories under cracked tooth syndrome which is classified by American Association of Endodontists (AAE)² as (Figure 1):

- Craze lines-confined to enamel
- Cuspal fracture-usually diagonal fractures that do not involve the pulp directly
- Cracked teeth-incomplete vertical fractures, often involving the pulp
- Split tooth-complete vertical fractures
- Vertical root fractures (VRFs)-longitudinal fractures, usually of endodontically treated teeth.

Vertical root fractures can be difficult to differentiate from failing endodontically treated teeth or teeth associated with periodontal disease. They usually occur in endodontically treated teeth, although occurrence in non-restored teeth has been described. In molar teeth, the fracture is most commonly bucco-lingual in

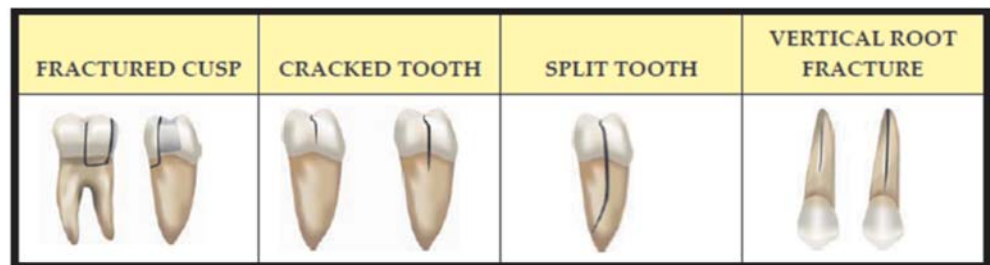


Figure 1: Schematic diagram representing different types of fractures

Corresponding Author:

Disha Agarwal

E-mail:

simpleeedisha@gmail.com

Received: 23rd December, 2014

Accepted: 15th April, 2015

Online: 10th May, 2015

orientation in individual roots. Mesio-distal fractures are less common. In anterior teeth, the fractures are commonly in a buccolingual direction. It was in 1983 that Pitts and Natkin⁴ extensively reviewed clinical and radiographic signs of vertical root fractures. The etiology tends to be multifactorial and the need to extract the tooth or the root when the definitive diagnosis is made is disappointing.

According to Pit and Natkin (1983) VRF can be of two types⁴:

- Complete fracture
- Incomplete fracture

Etiology of a Vertical Root Fracture⁵

- Physical traumatic injury
- Occlusal prematurities
- Repetitive parafunctional habits of heavy stressful chewing
- Resorption-induced pathologic root fractures
- Iatrogenic dental treatment: placement of posts and pins, tapping into place of a tightly fitting post or intracoronal restoration, endodontic treatment reducing remaining dentin thickness and intracanal forces from excessive compaction pressure during obturation.

Clinical findings

The clinical presentation of a vertical root fracture is extremely variable. The clinical signs and symptoms vary according to the position of the fracture, tooth type, time after fracture, and the periodontal condition of the tooth and the architecture of the bone adjacent to the fracture.

- Teeth with vertical root fractures often present with a long history of variable discomfort or soreness, usually associated with local chronic infection.
- The pain is usually mild to moderate in intensity.⁶ Rarely severe pain is associated in such cases. Vertically fractured teeth can also present with a history of pain on biting. Where a root filled tooth is associated with 'pain on biting' and accompanied by a 'bad taste', a vertical root fracture is most likely present.
- Bite test: A clinical test that simulates the chief complaint is the occlusal pressure test or biting test. Several methods exist, such as biting on an orangewood stick, toothpick, cotton applicator, a Burlew rubber disk, or a wet cotton roll. All have

the ability to simulate a bolus of food and allow pressure on the occlusal surfaces. The small cupped-out area on these instruments is placed in contact with the cusp to be tested. The patient is then asked to apply biting pressure with the opposing teeth to the flat surface on the opposite side of the device to elicit pain.

- Occasionally, the patient can be aware of a sharp cracking sound at the time of condensation of gutta-percha or the cementation of a post.⁶ Bleeding during condensation of obturating material and an apparent lack of resistance within the canal during condensation are also signs that a vertical root fracture is present.
- Selective Sensitivity: Vertical root fractures may manifest as a selective sensitivity when the tooth is percussed in a particular direction. The back end of a dental mirror handle is a useful instrument.⁵
- Swelling: if present the swelling is usually broad-based and mid-root in position. Palpation will often show swelling and tenderness over the root itself, but little swelling in the periapical region.
- When a sinus tract is present, it may be situated in or close to attached gingiva rather than in the apical region. Double or multiple sinus tracts are common.⁴ Where multiple sinus tracts are present one or more of these tracts may be located some distance from the involved tooth. The insertion of a gutta-percha point into each sinus tract can assist with diagnosis.
- A common feature of vertically root fractured teeth is the development of deep, narrow, isolated periodontal pockets (Figure 2). When the

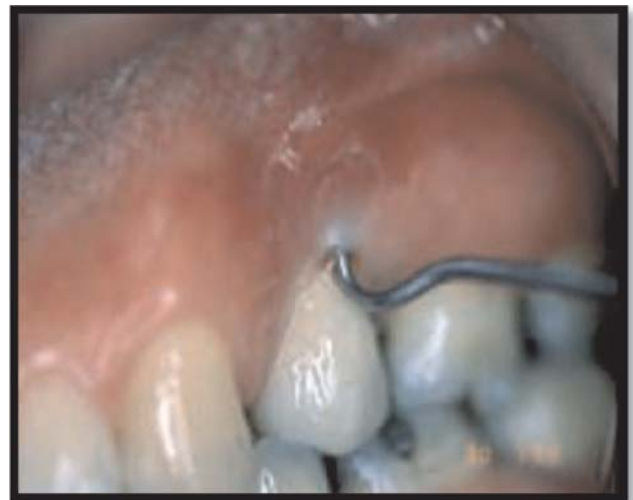

Figure 2: Deep narrow pocket in maxillary premolar

periodontal probe is inserted into this type of periodontal pocket, it is tight within the pocket, and the periodontal probe's movement from side to side is restricted. The probing pattern for a tooth with a vertical root fracture is different from that seen in teeth with periodontal disease, where the pocketing is fairly consistent in depth around a large part of the tooth. Deep probing in two positions on opposite sides of the infection is almost pathognomonic for the presence of a fracture.⁴

- A common feature is the dislodgement of a post or post crown. A root fracture should be suspected if an apparently well-fitting post or post core becomes dislodged⁹ (Figure 3).

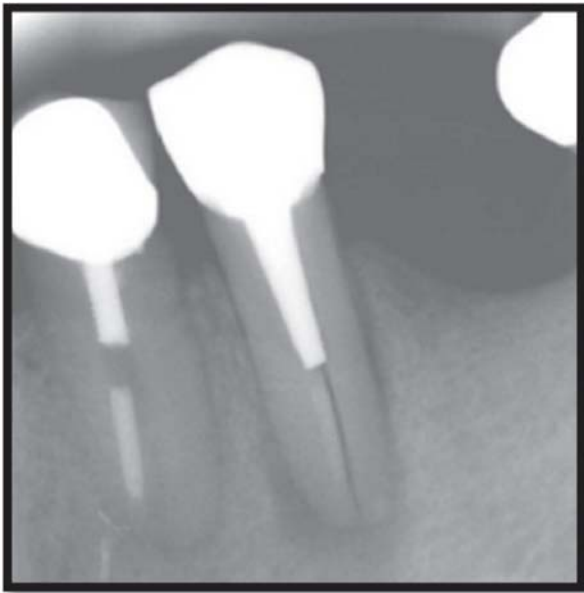


Figure 3: Space beside a root filling with dislodged post

- It is common for such teeth to have been treated repeatedly by surgery before the presence of a fracture is diagnosed. A vertical fracture should be considered a possibility when surgery fails for no obvious reasons.
- Transillumination and dyes: Methylene blue dye, when painted on the tooth surface with a cotton tip applicator, will penetrate into cracked areas. The excess dye may be removed with a moist application of 70% isopropyl alcohol. The dye will indicate the possible location of a crack. Directing a high-intensity light directly on the exterior surface of the tooth at the cementum–enamel junction (CEJ) may indicate the extent of the fracture. Teeth with fractures block

transilluminated light. The part of the tooth that is proximal to the light source will absorb this light and glow, whereas the area beyond this fracture will not have light transmitted to it and will be gray by comparison.⁵ Similarly another method requires a dye soaked cotton pellet to be placed followed by temporary restoration and evaluation of dye penetration in the next appointment.

Radiographic signs

While the clinical presentation of a vertical root fracture can be variable, radiographic signs are quite specific. These signs can vary considerably from case to case, depending on the angle of the X-ray beam in relation to the plane of fracture, the time after fracture and the degree of separation of the fragments.

- Separation of root fragments: When separation of root fragments occurs, the root fracture is clearly visible. Once separation of fragments has occurred, proliferation of granulation tissue often results in the rapid movement of the fragment away from the remaining root⁷ (Figure 4).
- Fracture lines along the root or root filling: Direct

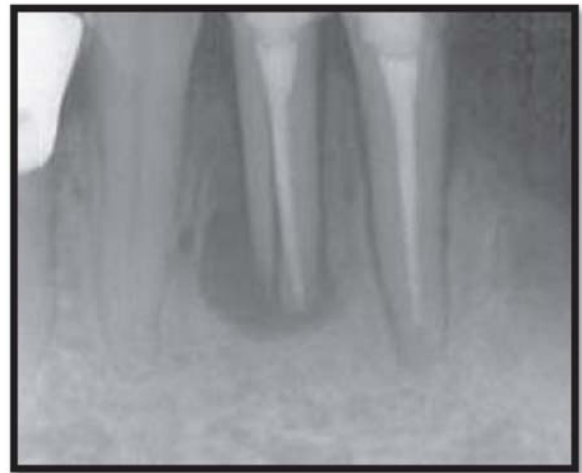

Figure 4: Separation of root fragments

evidence of a fracture can be seen as a vertical radiolucent line running across the root or the root filling. For the fracture to be seen the x-ray beam must pass almost directly down the fracture line. A four degree variation in the horizontal angulation of the film can prevent visualization of the fracture.⁸

- Space beside a root filling: Minor separation of fragments can result in the radiographic appearance of a vertical space adjacent to the root filling material in an otherwise well obturated canal. Vertical root fractures should be suspected if the root filling appears well condensed but is in close contact with only one wall of the root canal.⁹
- Space beside a post: When a post is present in a vertically root fractured tooth, slight separation of the fractured fragments can result in the appearance of a space between the edge of a root canal, which may be coated with cement, and the post itself.⁹
- Double images: When separation of fragments occurs in a direction other than parallel to the x-ray beam, overlapping of fragments may result in double images of the external root surface.⁹
- Radiopaque signs: Where a vertical root fracture is present prior to root filling, or occurs during the root filling procedure, extrusion of cement or root filling material can occur into the fracture site or apically. This “cement trail” can be seen up or across the root.⁵ It can be confused with the obturation passing through accessory canals, but the appearance is more diffuse in cases of vertical root fractures, with no observation of a symmetrical lateral canal passing from a main canal. Where separation of the fracture occurs during root filling, extension of root filling material through the apex can result in a tangle of accessory points at the apex called as “apical spaghetti”.⁹
- Widening of periodontal ligament space: Wide enlargement of the periodontal ligament around the whole length of the root is an indication that the tooth is vertically fractured. The radiographic appearance of bone loss is quite different from that seen in a periapical lesion where apical bone loss can occur but without destruction of the lamina dura along the root surface.
- Radiolucent halos: When the plane of fracture is at right angles to the X-ray beam, the pattern of bone loss appears wider and more diffuse than that seen in bucco-lingual fractures. Pitts and Natkin⁴ have described this appearance as a 'halo-like' radiolucency (Figure 5) running around the whole

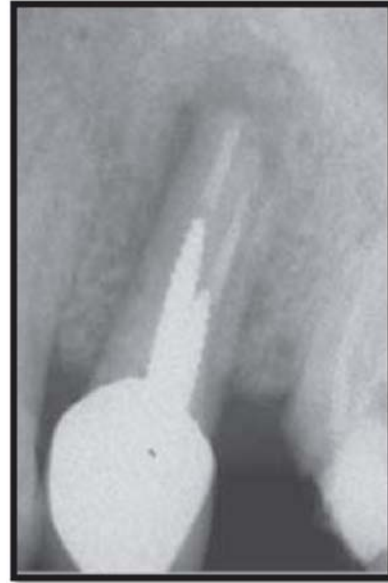


Figure 5: Halo like radiolucency

of the tooth. While the width of the diffuse bone loss may vary, a radiolucent halo which runs around the whole of the root surface is a classic sign of a vertical root fracture. The pattern of bone loss forms “V-shaped” radiolucency.

- Step-like bone defects: When the fracture runs obliquely across the root, or where the fracture does not extend into the apical portion, a characteristic step-like bone defect develops. Additional radiographic examination with the X-ray beam angled 15 degrees to the mesial or distal may provide a better view of the defect.¹⁰
- Isolated horizontal bone loss in posterior teeth: It is unusual for one tooth in a dentition to be severely involved with periodontal disease without involvement of other teeth. When only an isolated tooth shows bilateral horizontal bone loss the presence of a mesio-distal root fracture should be expected, particularly in the presence of apparently successful endodontic therapy.
- Unexplained bifurcation bone loss: Where bifurcation bone loss occurs for no apparent reason and without any obvious sign of apical pathosis, the presence of a vertical fracture through the bifurcation needs to be considered.⁹
- V-shaped diffuse bone loss on roots of posterior teeth: Where the buccal roots of maxillary molars or the roots of lower molars are vertically

fractured, the characteristic radiographic image of bone loss is a diffuse V-shaped radiolucency, widest at the crestal bone, narrowing towards the apex.⁴

- Resorption along the fracture line: This resorption may occur apically where it causes a J-shaped notch in the apical region, or longitudinally along the whole length of the fracture, giving the appearance of an irregular long resorptive defect running along the gutta-percha root filling.
- Dislodgement of retrograde filling material: It can occur due to inadequate retention.
- Other radiographic technology includes cone beam computed tomography (CBCT) and optical coherence tomography (OCT). Shemesh H et al¹¹ suggested optical coherence tomography as a promising non-destructive imaging method for the diagnosis of vertical root fractures. It is a high-resolution imaging technique that allows micrometer scale imaging of biologic tissues over small distances.

Direct visualization of the fracture

Direct observation of the fracture is the only sure way to confirm the presence of the fracture in many cases. Gentle retraction of the soft tissues in the region of the suspected fracture line with a flat plastic or other instrument (under anaesthetic if required) may be sufficient to view the fracture on the root surface. Location of the fracture can be assisted by passing a sharp probe lightly over the tooth surface. A 'clicking' sound can be heard as the probe is passed over the fracture line.⁴ Where this is not possible, reflection of a small flap is recommended in order to view the root and confirm the presence of a fracture (Figure 6).

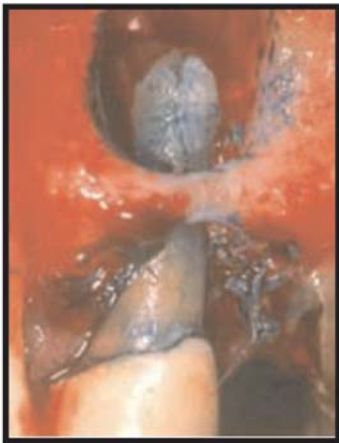

Figure 6: Methylene blue dye used to detect vertical root fracture under direct visualization

A fibre-optic light is a useful diagnostic tool, particularly where the fracture is not stained, or where separation of fragments has not occurred. A fracture may be observed extracoronally before endodontic treatment; its depth can be visualized intracoronally with the dental operating microscope after an endodontic access has been created.

Treatment

Treatment of vertically fractured teeth is difficult and is dependent on the tooth type as well as on the extent, duration and location of the fracture. A majority of vertical fractures involve the gingival sulcus and result in destruction of the periodontium to the apical extent of the fracture, due to ingress of bacteria and other irritants, resulting in alveolar bone loss in almost all teeth. Repair of the periodontium and the bone cannot occur in the presence of the bacterial infection.⁴ The aim of treatment is therefore to eliminate the fracture either non-surgically or surgically and the leakage of bacteria along the fracture plane. Multirouted teeth can often be successfully treated by resecting the fractured root, either by root amputation or hemisection.⁹

Glass ionomer cement, composite or cyanoacrylate may be used to bond the two fracture segments, preventing further propagation of the fracture. An in-vitro study assessing the resistance to fracture of root segments bonded with glass ionomer cement, composite resin, and cyanoacrylate concluded that the bond strengths of composite resin and cyanoacrylate were superior to glass ionomer cement.¹² Calcium hydroxide has been used to promote tissue repair and resolve osseous defects before the roots were restored. Teeth treated with calcium hydroxide, then 'reinforced' with glass ionomer cement, have shown healing at six month follow-up appointments.¹³

Trope and Rosenberg¹⁴ extracted both segments of a maxillary second molar and protected the periodontal ligament by soaking it with Hanks balanced salt solution, while bonding the segment with glass ionomer and subsequently replanting the tooth using Gore-tex membrane to establish a new periodontal attachment. After six months, they reported a reduction in pocket depth from 10 mm to 2-3 mm this was followed by crown placement after 1 year.

Takatsu et al.¹⁵ used orthodontic elastics to join the buccal and palatal segments of a vertically fractured maxillary second molar which were then sealed with a photocured resin liner followed by endodontic treatment and restoration with a cast crown.

An in vitro study by Arakawa S et al.¹⁶ proved CO₂ and Nd:YAG laser to be an ineffective way to fuse fractured tooth roots due to very high rise in temperature.

Prognosis:

Prognosis for posterior teeth is good, provided the fracture can be removed in its entirety. Prognosis for single rooted teeth is poor and extraction is often the treatment of choice.

CONCLUSION:

To conclude it can be rightly said that diagnosis is the art of identifying a disease from its signs and symptoms. Although scientific devices can be used to gather some information, diagnosis is still primarily an art because it is the thoughtful interpretation of the data that leads to a diagnosis. The constant ingress of bacteria into vertical root fracture provides an open pathway from the oral cavity to the supporting periodontal and alveolar tissues resulting in various clinical and radiological signs. It is important that clinician has a sound knowledge about the subject and is equipped with the recent diagnostic technologies so that accurate diagnosis of the vertical root fracture can be made and best possible treatment can be rendered to the patient.

REFERENCES:

- Gibbs JW. Cuspal fracture odontalgia. *Dent Dig.* 1954; 60:158-163.
- Ingle IJ, Bakland LK, Baumgartner JC, editors. *Ingle's endodontics.* 6th ed. Hamilton: BC Decker Inc. Tamse A. Vertical root fractures of endodontically treated teeth 2008; p.676-689.
- Walton RE, Michelich RJ, Smith GN. The histopathogenesis of vertical root fractures. *J Endod* 1984; 10(2):48–56.
- Pitts DL, Natkin E. Diagnosis and treatment of vertical root fractures. *J Endod* 1983; 9(8):338-346.
- Hargreaves KM, Cohen S, editors. *Pathways of pulp.* 10th ed. St. Louis: Mosby, Elsevier. Berman LH, Hartwell GR. Chapter 1, Diagnosis 2010; p. 2-39.
- Meister F Jr, Lommel TJ, Gerstein H. Diagnosis and possible causes of vertical root fractures. *Oral Surg Oral Med Oral Pathol* 1980; 49(3):243-253.
- Meister F Jr, Lommel TJ, Gerstein H. An additional clinical observation in two cases of vertical root fracture. *Oral Surg Oral Med Oral Pathol* 1981; 52(1):91-96.
- Rud J, Ommel KA. Root fractures due to corrosion. Diagnostic aspects. *Scand J Dent Res* 1970; 78(5):397-403.
- Moule AJ, Kahler B. Diagnosis and management of teeth with vertical root fractures. *Aus Dent J* 1999; 44(2):75-87.
- Abou-Rass M. Crack lines: The precursors of tooth fractures – their diagnosis and treatment. *Quintessence Int.* 1983; 14(4):437-447.
- Shemesh H, Van Soest G, Wu MK, Wesselink PR. Diagnosis of vertical root fractures with optical coherence tomography. *J Endod* 2008; 34(6):739-42.
- Friedman S, Moshonov M, Trope M. Resistance to vertical fracture of roots, previously fractured and bonded with glass ionomer cement, composite resin and cyanoacrylate cement. *Endod Dent Traumatol* 1993; 9(3):101-105.
- Barkhordar RA. Treatment of vertical root fractures: a case report. *Quintessence Int.* 1991; 22:707-709.
- Trope M, Rosenberg ES. Multidisciplinary approach to the repair of vertically fractured teeth. *J Endod* 1992; 18(9):460-463.
- Takatsu T, Sano H, Burrow MF. Treatment and prognosis of a vertically fractured maxillary molar with widely separated segments: a case report. *Quintessence Int.* 1995; 26:479-484.
- Arakawa S, Cobb CM, Rapley JW, Killoy WJ, Spencer P. Treatment of root fracture by CO₂ and ND:Yag lasers: An in vitro study. *J Endod* 1996; 22(12):662-667.