

MANAGEMENT OF MANDIBULAR FRACTURE IN 5 YEAR OLD CHILD : A CASE REPORT

Priyanka Dhawan¹, Taranjot Kaur², Sanjay Chachra³, Kamaljeet Kaur⁴

¹PG Student, Department of Paedodontics & Preventive Dentistry, Swami Devi Dyal Hospital and Dental College, Haryana, India

²Reader, Department of Paedodontics & Preventive Dentistry, Swami Devi Dyal Hospital and Dental College, Haryana, India

³Professor & Head, Department of Paedodontics & Preventive Dentistry, Swami Devi Dyal Hospital and Dental College, Haryana, India

⁴Sr. Lecturer, Department of Paedodontics & Preventive Dentistry, Swami Devi Dyal Hospital and Dental College, Haryana, India

ABSTRACT

Trauma induced maxillofacial injuries may affect function as well as esthetics in children. In hospitalized paediatric trauma patients, mandibular fractures are the most common. Boys are affected twice than girls. In children, management of mandibular fractures differ somewhat from that in adults. The objective of treatment is to restore the underlying bony architecture in a stable and non invasive fashion to pre injury position. Closed reduction method is preferred in most paediatric cases. This case report demonstrates the use of fabricated acrylic splint in the stabilization and fixation of a mandibular body fracture in a 5 yr old patient.

Keywords: Closed Reduction, Mandibular Fractures, Paediatric Trauma

INTRODUCTION

Most frequently targeted site of trauma is oral and maxillofacial region.¹ Paediatric dentist commonly encounter traumatic injuries in children which may range from minor contusion injuries to fractures of the jaw bones.² The frequency of facial fractures is lower in children (5-15%) as compared to adults.³ In hospitalized paediatric trauma patients, mandibular fractures are the most common (56%) facial skeletal injury and boys are affected twice frequently than girls.⁴ Closed reduction is the preference of treatment in most cases of paediatric fractures and hence knowledge of methods to accomplish this is necessary.⁵

Case Report: A 5 - year old boy reported to the Department of Paedodontics and Preventive dentistry, Swami Devi Dyal Hospital and Dental College, Barwala, Panchkula two days after encountering trauma due to road accident. Patient had severe, continuous pain accompanied with swelling in the right parasymphysis region of the face. Parents gave no history of unconsciousness, convulsions, vomiting, bleeding from nose or ears and

was well oriented to time and place after the accident. There was difficulty in opening and closing of mouth. Clinical examination revealed step deformity of the right lower border of the mandible with deviation to right side. The patient had primary dentition. Intraoral examination revealed derangement of occlusion. The fractured segments were not mobile. A hematoma was present on the buccal aspect of right parasymphysis region. Orthopantomograph revealed right parasymphysis mandibular fracture. Radiographic examination revealed discontinuity of the right border of mandible; fracture line was seen running obliquely downward and backward from canine to 1st premolar region. (Figure 1). Blood investigations were carried out and the results were within normal range.

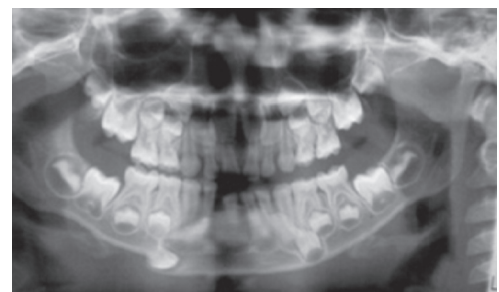

Figure 1: Pre operative Orthopantomograph

Corresponding Author:

Priyanka Dhawan

E-mail:

priyanka_dhawan@ymail.com

Received: 22nd January, 2015

Accepted: 29th March, 2015

Online: 10th May, 2015

It was decided to reduce the mandible by closed reduction using fabricated acrylic splint followed by circummandibular wiring. Treatment plan was explained to patient's parents and their written informed consent was obtained. The alginate impressions of upper and lower arch were made and working models were prepared. An occlusal acrylic splint was fabricated on the lower cast. After getting the anaesthetic clearance, the patient was prepared for the surgery under conscious sedation. Reduction of the fractured segments was done by bimanual maneuver, followed by fixation of acrylic splint and circummandibular wiring (Figure 2). This was done

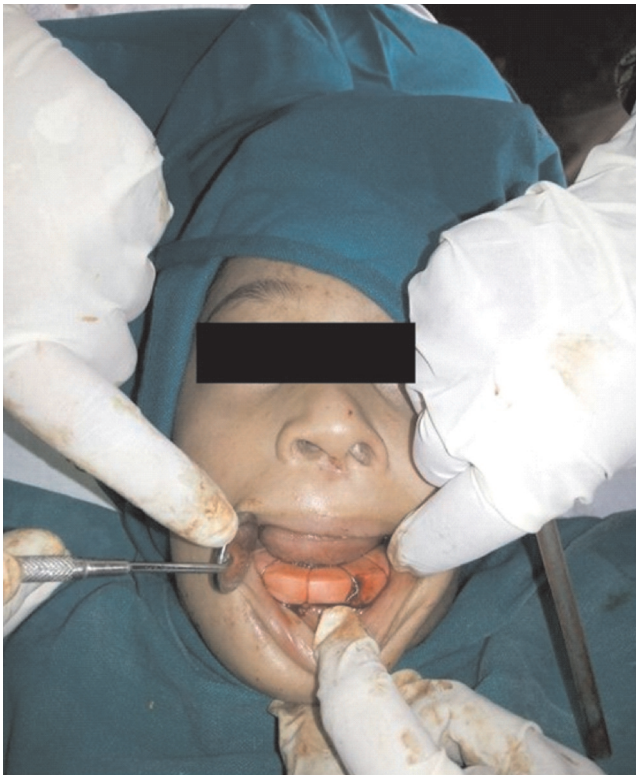

Figure 2: Post operative photograph with positioned splint on mandibular arch

bilaterally in the canine region. Fracture reduction and stabilization was conducted according to treatment plan. Recovery from conscious sedation was uneventful. Postoperative antibiotics and analgesics were continued for three days. An orthopantomograph was made post operatively on the same day to confirm the approximation of the fractured ends (Figure 3). The patient was discharged on the same day and was given the instructions of a soft diet and maintenance of good oral hygiene.

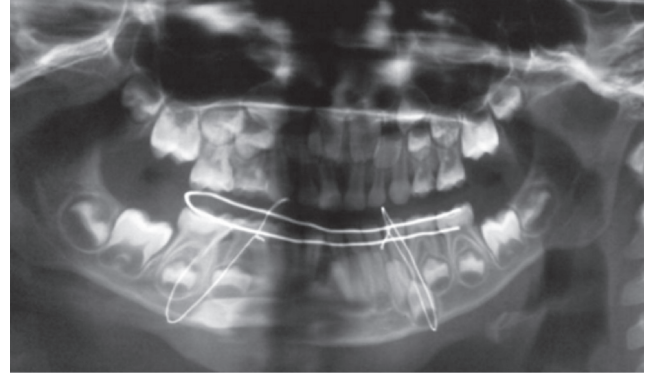


Figure 3: Post operative Orthopantomograph

The patient was first recalled after three days then after one week. The circum-mandibular wiring and splint were removed under local anesthesia on third post operative week. Orthopantomograph revealed satisfactory approximation of fractured ends (Figure 4). Postoperative recovery was uneventful and occlusion achieved was satisfactory. The patient is still under follow up.

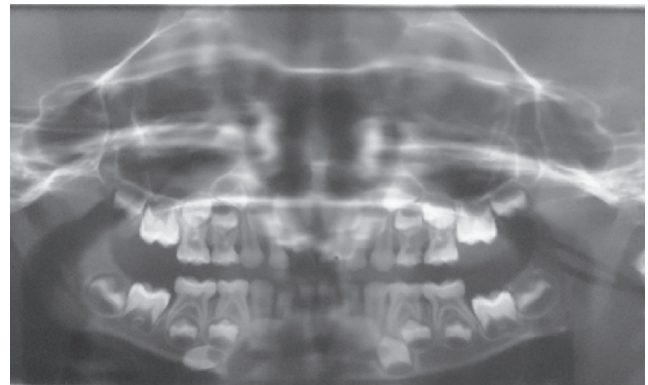


Figure 4: Orthopantomograph after splint removal showing satisfactory approximation of fracture ends

DISCUSSION

There are two main considerations in the management of fractured mandible in children i.e primary teeth are difficult to wire and growing jaws heal exceedingly fast.⁷ The objectives of treatment of mandibular fractures are to restore normal occlusion, stability and function.³ Nondisplaced body and symphysis fractures are treated by close observation, blenderized diet, and avoidance of physical activities. If a body or symphysis fracture is displaced, closed reduction and immobilization is performed. The method of immobilization depends on the child's chronological age and the stage of dental development. In children under 2 years of age, the primary dentition may not be

fully erupted and root development may be incomplete. In the mixed dentition stage, only the 1st permanent molars may be adequate for circum-dental wires. If possible, arch bars are placed, and the jaw is immobilized with elastics. If the teeth are inadequate, a gunning or lingual splint can be used to immobilize the fracture site. If the fracture is not immobilized adequately by the splint, then intermaxillary fixation is used.⁴ In paediatric craniofacial surgery, the use of absorbable plates and screws have virtually no side effect on growing facial skeleton but there is still a risk of damaging unerupted teeth during the drilling process. A conservative approach (observation or closed reduction) is the best approach to consider for mandible fractures.⁵

Kocabay C et al, 2007 treated paediatric mandibular fracture with prefabricated surgical splint which is conservative and more reliable than open reduction or intermaxillary fixation techniques.⁵ John B et al, 2010 described a case of paediatric mandibular body fracture which was immobilized, fixed with the acrylic splint and retained by circummandibular wiring. Results revealed that there was no mobility at the fracture site and satisfactory occlusion was achieved.⁸ A case was presented by Khatri A et al, 2011 which was successfully treated by means of applying direct interdental wiring combined with an acrylic splint.³

The advantages of using fabricated acrylic splint over other methods are that it is less time consuming, easy to apply, remove and cost-effective for conservative treatment of paediatric mandibular fracture. Moreover, they provide maximum stability during the healing

period. There is minimal trauma to the adjacent anatomic structures and thus are more comfortable for young patients.³ It should always be taken in contemplation that in paediatric facial trauma cases periodical long-term follow-up is essential for early determination of possible growth disturbances.⁵

Conclusion: This case report demonstrates that the use of a fabricated acrylic splint is a reliable and noninvasive procedure in the stabilization and fixation of a mandibular body fracture that must be considered in selected cases. A splint limits the distress and morbidity in paediatric patients that may be associated with maxillomandibular fixation or open reduction and internal fixation.⁶

REFERENCES:

1. Bregagnolo LA et al. Oral and maxillofacial trauma in brazilian children and adolescents. *Braz Dent J* 2013; 24:398-401
2. Prabhakar AR, Rai KK, Prahlad DA modified surgical approach to a case of mandibular fracture in a 5-year-old girl. *Contemp Clin Dent* 2013; 4:81-3
3. Khatri A, Kalra N. A conservative approach to pediatric mandibular fracture management: outcome and advantages. *Indian J Dent Res* 2011; 22:873-6
4. Kaban LB. *Pediatric oral and maxillofacial surgery*. 2nd ed. Philadelphia: WB Saunders; 1990:441-62
5. Kocabay C, Atac MS, Oner B, Gungor N. The conservative treatment of pediatric mandibular fracture with prefabricated surgical splint: a case report. *Dent Traumatol* 2007; 23: 247-50
6. Kruger GO. *Oral and maxillofacial surgery*. 6th edition. CV Mosby Company & Jaypee; 1984 : 417-22
7. Qadri GW, Mokhtar SM. Paediatric mandibular fractures: report of a case. *Dent Traumatol* 2008; 24:67-70
8. John B, John RR, Stalin A., Elango I. Management of mandibular body fractures in pediatric patients: A case report with review of literature. *Contemp Clin Dent* 2010; 1:291-6

Source of Support: Nil, Conflict of Interest: None Declared